News and Views

Nonpathological Asymmetry in LB1 (*Homo floresiensis*): A Reply to Eckhardt and Henneberg

Dean Falk,[1]* Charles Hildebolt,[2] Kirk Smith,[2] Peter Brown,[3] William Jungers,[4] Susan Larson,[4] Thomas Sutikna,[5] and Fred Prior[2]

[1]*School for Advanced Research, Santa Fe, NM 87505*
[2]*Mallinckrodt Institute of Radiology, Washington University School of Medicine, St. Louis, MO 63110*
[3]*Department of Palaeoanthropology, Faculty of Arts and Sciences, University of New England, Armidale NSW 2351, Australia*
[4]*Department of Anatomical Sciences, Stony Brook University School of Medicine, Stony Brook, NY 11794*
[5]*National Research and Development Centre for Archeology, Jakarta, Indonesia*

Eckhardt and Henneberg's commentary contains several omissions and misstatements. First, changes due to postmortem distortion, erosion, and fracture of skeletal elements from archeological contexts may be confused with evidence of disease or trauma. The LB1 *Homo floresiensis* skeleton was recovered from a depth of ~6 m, in sector VII, from Liang Bua cave (Morwood et al., 2004). The skull was found resting on its base, with the associated mandible disarticulated, rotated 180° and pressing against the right zygomatic arch. The bone was damp, somewhat chalky and extremely soft, and the left frontofacial region and posterior frontal were damaged during discovery. The skull was removed in a block of sediment and taken to Jakarta (Brown et al., 2004). Cleaning, reconstruction, and preliminary conservation of the skull were undertaken by one of us (PB). On removing the surrounding sediment, it was apparent that the right half of the coronal suture had sprung open postmortem, the right zygomatic arch was distorted, the cranial vault was full of cracks, and the right parietal was slightly distorted (see Fig. 1). In other words, taphonomic distortion partially contributed to the asymmetry seen in LB1's skull.

Eckhardt and Henneberg report that Jacob et al. (2006) used the "standard clinical approach" of Peck and Peck (1970) to obtain measurements that revealed pathological asymmetry of LB1's skull. However, Peck and Peck used a method for assessing soft-tissue asymmetry in which a mirror image was created based on the midpoint of the interpupillary distance and the midpoint of the upper lip. Standards evolve and, more recently, Peck et al. used radiographic cephalograms to assess craniofacial skeletal asymmetry; they concluded that "Three-dimensional radiography by either computed tomographic (CT) scans or the digitized integration of sagittal and posteroanterior cephalograms probably offers the most promise today in the analysis of multiplane skeletal deformity, including asymmetry" (1991:45–46).

The asymmetry measurements of Jacob et al. (2006) were collected from corresponding points for seven landmarks located on opposite sides of a midline that was defined as the vertical axis from vertex on the cranium to gnathion on the (distorted) mandible in a 2D digital photograph of LB1's face. Elsewhere, we used 3D-CT data from LB1's neurocranium to demonstrate that visually assessing the degree of facial asymmetry based on hypothetical midlines determined from 2D photographs is scientifically unsound and acknowledged that "Performing mirror imaging even with 3D images is problematic; however…performing mirror imaging with 3D data is far superior to performing mirror imaging with 2D representations of a 3D object" (Falk et al., 2009b: 57, Fig. 5). Small errors in alignments and assessments of the midlines can lead to quite different mirror images. In our 3D-CT reconstruction, the mandible of LB1 was purposefully excluded from our measurements because it evinced postmortem distortion and would not occlude and articulate properly with the skull (Brown and Maeda, 2009; Kaifu et al., 2009).

Jacob et al. quantified lateral deviations from their questionable midline in a 2D photograph "in pixels rather than absolute units (millimeters) to eliminate or minimize differences in depth of field…." (Jacob et al., 2006: supporting information). The pixel data were asymmetrical and favored mostly the right side, and the authors claimed that they represented "Two or more times the levels of asymmetry accepted as normal in anthropological and clinical contexts, as documented in the text" (*ibid*). The text, however, summarized an older literature that addressed fluctuating asymmetries of neurocranial measurements in millimeters, rather than pixels, and that were mostly recorded using mechanical measurements directly from skulls. In two-dimensional representations of three-dimensional objects, information is lost, and measurements made from the mid-sagittal planes are particularly problematic because landmarks are located in different coronal planes (Varghese et al., 2010). Further, it is not clear what the relationship is, if any, between pixels and distances from a hypothetical midline on a 2D photograph and how pixels could correct for depth of field issues. There is no description of the imaging parameters, so it is unclear whether film images were obtained and digitized or if a digital camera was used, nor is the resolution of the image used for making measurements given.

Based on their undescribed conversion of pixels to millimeters, the authors state that absolute difference between sides was 2.14 mm, and claimed that this represents a difference two or more times the acceptable level of asymmetry. In Peck et al. (1991), however, the mean asymmetry was 3.54 mm with a 0–12 mm range, and in Farkas and Cheung (1981), cited by Jacob et al. (2006),

*Correspondence to: Dean Falk, School for Advanced Research, Santa Fe, NM 87505. E-mail: falk@sarsf.org

Received 16 June 2010; accepted 9 July 2010

DOI 10.1002/ajpa.21392
Published online 31 August 2010 in Wiley Online Library (wileyonlinelibrary.com).

© 2010 WILEY-LISS, INC.

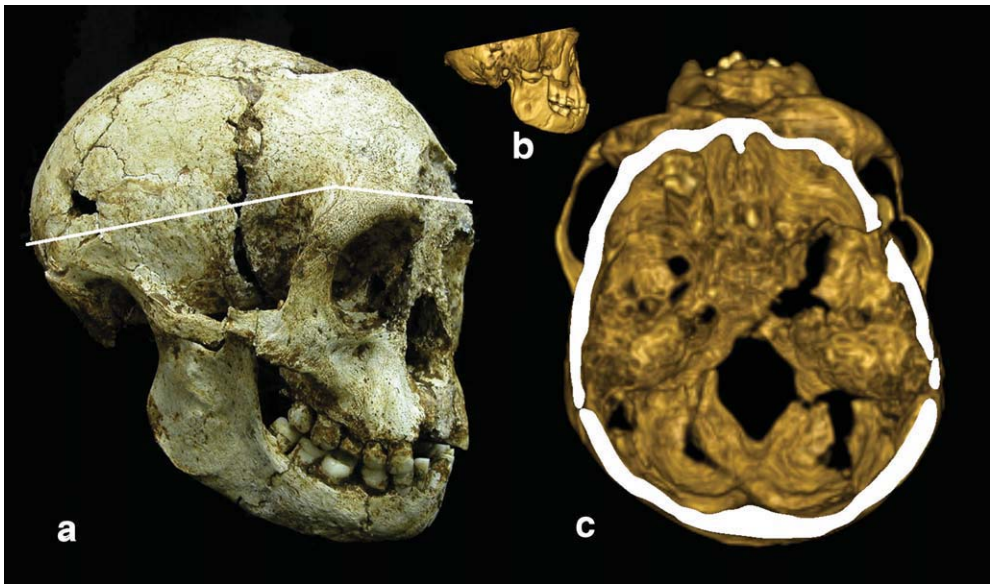

Fig. 1. Evidence of postmortem distortion in LB1 *Homo floresiensis*. **a**: View of right side showing open coronal suture, distorted zygomatic arch, pressure cracks in the cranial vault, and postero-laterally distorted right parietal, (**b**) level of section shown in c, (**c**) Section through a 3D volumetric reconstruction showing asymmetry in parietal shape and distortion of the right zygomatic region. A color version of this figure can be found online. [Color figure can be viewed in the online issue, which is available at wileyonlinelibrary.com.]

the mean asymmetry in normal children 6 to 18 years of age was 3 mm. Eckhardt and Henneberg further state that "Precision is important because differences of a few percent distinguish normal from abnormal asymmetry," although no precision estimate is provided for the mirror imaging procedure by Jacob et al. (2006). We are well aware of the importance of measurement precision and present elsewhere in supporting online material our measurement precision (Falk et al., 2005). The claim that LB1 exhibited *abnormal* neurocranial asymmetry remains an unsubstantiated assertion by Jacob et al. (2006), as it is in this article.

Nevertheless, as shown in superior view Fig. 1c, LB1 has an asymmetric head (plagiocephaly) characterized by left-sided flattening in the occipitoparietal region (Brown et al., 2004; Falk et al., 2005, 2009a; Kaifu et al., 2009). This is not due to lambdoid craniosynostosis (Smartt et al., 2007) because the lambdoid sutures were visible (endocranially) on the virtual endocast that was processed from CT data collected from the original specimen (Falk et al., 2005: Fig. 3) and because LB1's skull lacks other diagnostic characteristics such as occipito-mastoid bossing (Huang et al., 1998; Kaifu et al., 2009). Although the location, morphology, and preservation of LB1's cranial flattening is consistent with positional plagiocephaly associated with the habit of placing infants in supine sleeping positions (Argenta et al., 1996; Peitsch et al., 2002; Robinson and Proctor, 2009; Brown, in press) or feeding infants preferentially from one side by breast or bottle (Boere-Boonekamp and van der Linden-Kuiper, 2001), LB1 was an adult, and the extent to which positional plagiocephaly existed and improved spontaneously as individuals matured in the past is not clear. The asymmetrical shape of LB1's skull/endocast is also consistent with normal human developmental skull/brain shape asymmetries (petalias) that are associated with brain lateralization and sexual dimorphism that began during fetal life (Falk et al., 2005, 2009a; Kivilevitch et al., 2010) as well as with human genes that are differentially expressed between the right and left hemispheres (Sun et al., 2005).

Contrary to the assumption that is inherent in Eckhardt and Henneberg's commentary as well as in the clinical literature on plagiocephaly, asymmetrical skull/brain shape is the *norm* for adult humans, with the predominant pattern combining a wider and more protuberant frontal lobe on the right side with a wider and more protuberant occipital lobe on the left, known as the Yakovlevian torque (Galabruda et al., 1978; Chui and Damasio, 1980; LeMay, 1984; Kivilevitch et al., 2010). This torque is statistically correlated with right-handedness, whereas its reverse (right occipital combined with left frontal petalia) is associated with left-handedness (LeMay, 1977; LeMay et al., 1982), especially in women who are characterized by the most extreme reversed petalias (Bear et al., 1986) as is the case for LB1 (Falk et al., 2005, 2009a,b). (Eight of the nine individuals with the most extreme petalia reversals in Bear et al.'s sample of 66 adults [30 men, 36 women] were women.) Petalia patterns have been quantified for nonhuman primates and early hominins (LeMay et al., 1982), and the particularly marked skewing of the brains/skulls of modern humans is believed to be the result of a prolonged evolutionary trend for increased brain and behavioral (e.g., handedness) lateralization (Kivilevitch et al., 2010; Falk et al., 2009a).

Eckhardt and Henneberg also ignore published data that refute prior claims of excessive asymmetry in the postcranium. The paired femora, patellae, tibiae, fibulae, and foot bones of LB1 are remarkably symmetrical by any standard (Jungers et al., 2009; Auerbach and Ruff, 2006). CT-scans also reveal no pronounced asymmetry in the amount and distribution of cortical bone (and in overall cross-sectional shape) in the femora and tibiae of LB1 (Jungers et al., 2010). In other words, asymmetry in LB1 is limited to the skull and is explained parsimoni-

ously by petalias/plagiocephaly and some degree of taphonomic distortion. LB1's overall cranial asymmetry is not extreme (Baab and McNulty, 2009) and certainly does not signal a systemic, body-wide pathology. Although research is needed to clarify the relationship between normal adult petalia patterns and positional plagiocephaly, the asymmetries of LB1's cranium "do not support the claim that the individual suffered from severe developmental abnormalities, nor do they undermine the holotype status of LB1" (Kaifu et al., 2009:184). Eckhardt and Henneberg also continue to assert without substantiation that LB1 suffers from microcephaly despite the fact that "the current evidence for pathologies in the form of microcephaly and disordered growth is not convincing" (Aiello, 2010:176; see also Falk et al., 2007a,b).

ACKNOWLEDGMENTS

The authors are deeply grateful to Michael Morwood of the University of Wollongong, NSW, Australia, and to Jatmiko and E. Wahyu Saptomo of the National Research and Development Centre for Archeology, Jakarta, Indonesia, for their input and collabortion on our work on *Homo floresiensis*.

LITERATURE CITED

Aiello LC. 2010. Five years of *Homo floresiensis*. Am J Phys Anthropol 142:167–179.

Argenta LC, David LR, Wilson JA, Bell WO. 1996. An increase in infant cranial deformity with supine sleeping position. J Craniofacial Surg 7:5–11.

Auerbach BM, Ruff CB. 2006. Limb bone bilateral asymmetry: variability and commonality among modern humans. J Hum Evol 50:203–218.

Baab KL, McNulty KP. 2009. Size, shape, and asymmetry in fossil hominins: the status of the LB1 cranium based on 3D morphometric analyses. J Hum Evol 57:608–622.

Bear DM, Schiff D, Saver J, Greenberg M, Freeman R. 1986. Quantitative analysis of cerebral asymmetry; fronto-occipital correlation, sexual dimorphism and association with handedness. Arch Neurol 43:598–603.

Boere-Boonekamp MM, van der Linden-Kuiper LT. 2001. Positional preference: prevalence in infants and follow-up after two years. Pediatrics 107:339–343.

Brown P. Nacurrie 1: mark of ancient Java, or a caring mother's hands, in terminal Pleistocene Australia? J Hum Evol, doi:10.1016/j.jhevol.2010.05.007.

Brown P, Maeda T. 2009. Liang Bua *Homo floresiensis* mandibles and mandibular teeth: a contribution to the comparative morphology of a new hominin species. J Hum Evol 57:571–596.

Brown P, Sutikna T, Morwood M, Soejono R. 2004. A new small-bodied hominin from the Late Pleistocene of Flores, Indonesia. Nature 431:1055–1061.

Chui HC, Damasio AR. 1980. Human cerebral asymmetries evaluated by computed tomography. J Neurol Neurosurg Psychiatry 43:873–878.

Falk D, Hildebolt C, Smith K, Morwood MJ, Sutikna T, Brown P, Jatmiko, Saptomo EW, Brunsden B, Prior F. 2005. The brain of LB1, *Homo floresiensis*.. Science 308:242–245.

Falk D, Hildebolt C, Smith K, Morwood MJ, Sutikna T, Jatmiko, Saptomo EW, Imhof H, Seidler H, Prior F. 2007a. Brain shape in human microcephalics and *Homo floresiensis*.. Proc Natl Acad Sci USA 104:2513–2518.

Falk D, Hildebolt C, Smith K, Morwood MJ, Sutikna T, Jatmiko, Saptomo EW, Prior F. 2009a. LB1's virtual endocast, microcephaly, and hominin brain evolution. J Hum Evol 57:597–607.

Falk D, Hildebolt C, Smith K, Jungers WJ, Larson S, Morwood MJ, Sutikna T, Jatmiko, Saptomo EW, Prior F. 2009b. The type specimen (LB1) of *Homo floresiensis* did not have Laron Syndrome. Am J Phys Anthropol 140:52–63.

Falk D, Hildebolt CG, Smith KE, Prior F. 2007b. LB1's virtual endocast: implications for hominin brain evolution. In: Indriati E, editor. Proceedings international seminar on southeast Asian paleoanthropology: recent advances on southeast Asian paleoanthropology and archaeology. Yogyakarta, Indonesia: Laboratory of Bioanthropology and Paleoanthropology, Faculty of Medicine Gadjah Mada University. p 37–46.

Farkas LG, Cheung G. 1981. Facial asymmetry in healthy North American Caucasians. An anthropometrical study. Angle Orthod 51:70–77.

Galaburda AM, LeMay M, Kemper TL, Geschwind N. 1978. Right-left asymmetrics in the brain. Science 199:852–856.

Huang MH, Mouradian WE, Cohen SR, Gruss JS. 1998. The differential diagnosis of abnormal head shapes: separating craniosynostosis from positional deformities and normal variants. Cleft Palate Craniofac J 35:204–211.

Jacob T, Indriati E, Soejono RP, Hsu K, Frayer DW, Eckhardt RB, Kuperavage AJ, Thorne A, Henneberg M. 2006. Pygmoid Australomelanesian *Homo sapiens* skeletal remains from Liang Bua. Flores: population affinities and pathological abnormalities. Proc Natl Acad Sci USA 103:13421–13426.

Jungers W, Farke A, Sutikna T, Ruff C, Shackleford L, Stock J, Carlson K, Pearson O, Grine F, Morwood M. 2010. Long-bone geometry and skeletal biomechanics in *Homo floresiensis*. Am J Phys Anthropol 141 (suppl S50):137.

Jungers WL, Larson SG, Harcourt-Smith W, Morwood MJ, Sutikna T, Due RA, Djubiantono T. 2009. Descriptions of the lower limb skeleton of *Homo floresiensis*. J Hum Evol 57:538–554.

Kaifu Y, Baba H, Kurniawan I, Sutikna T, Saptomo EW, Jatmiko, Due Awe R, Kaneko T, Aziz F, Djubiantono T. 2009. Brief communication: "pathological" deformation in the skull of LB1, the type specimen of *Homo floresiensis*.. Am J Phys Anthropol 140:177–185.

Kivilevitch A, Archiron R, Zalel Y. 2010. Fetal brain asymmetry: in utero sonographic study of normal fetuses. Am J Obstet Gyn 202:359.e1–e8.

LeMay M. 1977. Asymmetries of the skull and handedness. Phrenology revisited. J Neuro Sci 32:243–253.

LeMay M. 1984. Radiological, developmental and fossil asymmetries. In: Geschwind N, Galaburda AM, editors. Cerebral dominance: the biological foundations. Cambridge, MA: Harvard University Press. p 26–42.

LeMay M, Billig MS, Geschwind N. 1982. Asymmetries of the brains and skulls of nonhuman primates. In: Armstrong E, Falk D, editors. Primate brain evolution, methods and concepts. New York: Plenum Press. p 263–277.

Morwood MJ, Soejono RP, Roberts RG, Sutikna T, Turney CSM, Westaway KE, Rink WJ, Zhao JX, van den Bergh GD, Due RA, et al. 2004. Archaeology and age of a new hominin from Flores in eastern Indonesia. Nature 431:1087–1091.

Peck H, Peck S. 1970. A concept of facial esthetics. Angle Orthod 40:284–318.

Peck S, Peck L, Kataja M. 1991. Skeletal asymmetry in esthetically pleasing faces. Angle Orthod 61:43–48.

Peitsch WK, Keefer CH, LaBrie RA, Mulliken JB. 2002. Incidence of cranial asymmetry in healthy newborns. Pediatrics 110:1–8.

Robinson S, Procotor M. 2009. Diagnosis and management of deformational plagiocephaly. J Neurosurg Pediatr 3:284–295.

Smartt JM Jr, Reid RR, Singh DJ, Bartlett SP. 2007. True lambdoid craniosynostosis: long-term results of surgical and conservative therapy. Plast Reconstr Surg 120:993–1003.

Sun T, Patoine C, Abu-Khalil A, Visvader J, Sum E, Cherry TJ, Orkin SH, Geschwind DH, Walsh CA. 2005. Early asymmetry of gene transcription in embryonic human left and right cerebral cortex. Science 308:1794–1798.

Varghese S, Kailasam V, Padmanabhan S, Vikraman B, Chithranjan A. 2010. Evaluation of the accuracy of linear measurements on spiral computed tomography-derived three-dimensional images and its comparison with digital cephalometric radiography. Dentomaxillofac Radiol 39:216–23.